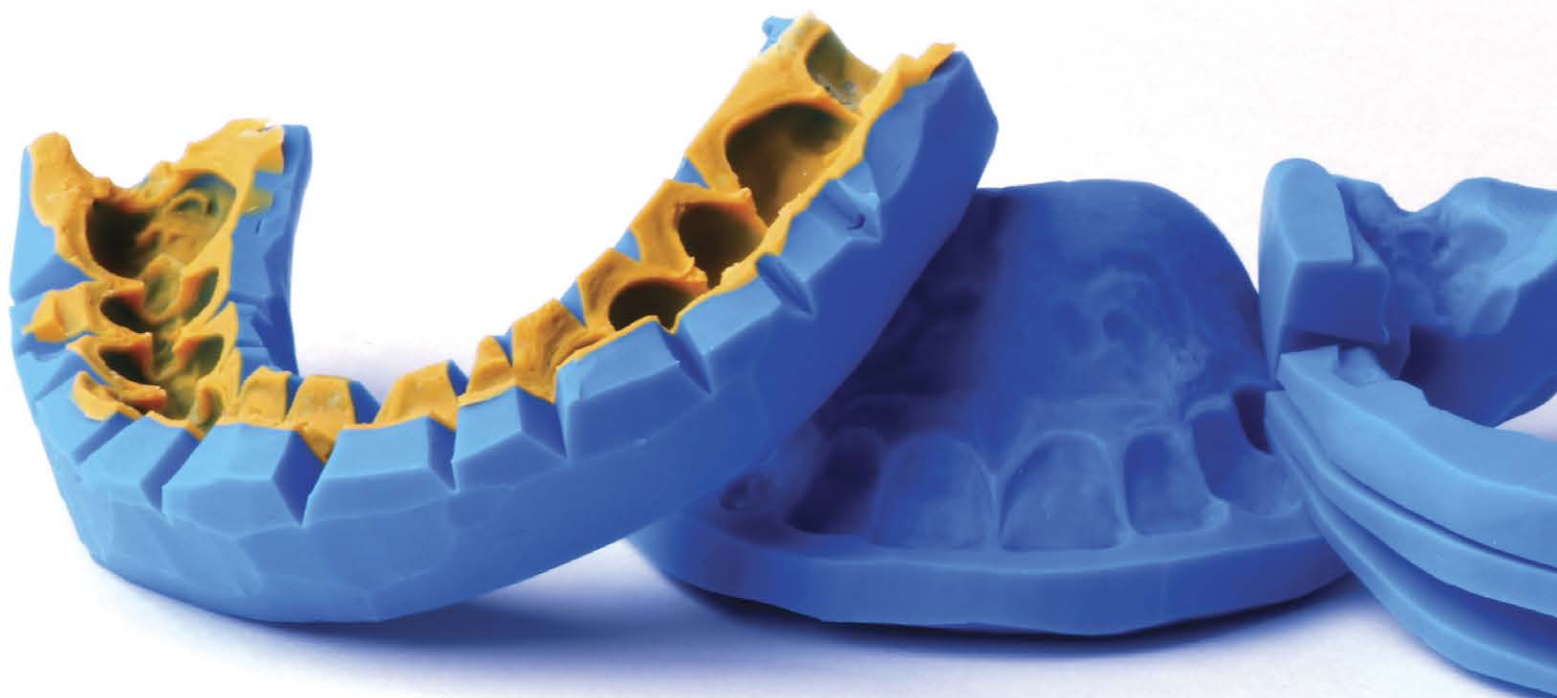

# PREPARATION GUIDES: 10 STEPS TO MAXIMIZE SUCCESS FOR VENEER PREPARATION



Zachary S. Sisler, DDS

## Abstract

The success of an indirect porcelain restoration hinges on the dentist's and laboratory technician's ability to work symbiotically. By starting with a diagnostic wax-up from the technician, the dentist can perform a custom-driven preparation design. Through the use of preparation guides, he or she can begin to envision the final restorative material volume needed, ultimately allowing for a smooth and properly prepared tooth. This article focuses on four specific preparation guides and the techniques to use them intraorally.

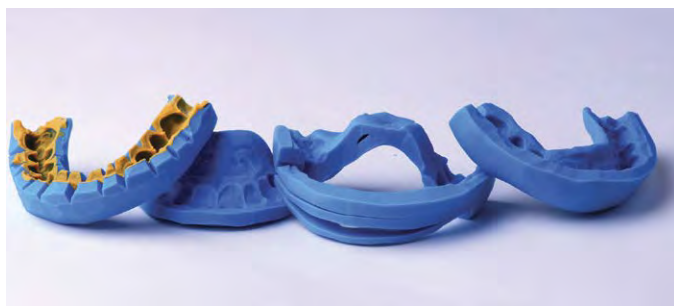**Key Words:** preparation guides, treatment planning, initial depth cut, incisal edge, facial, lingual/occlusal reduction, veneer preparation

**Bonus content!**

This article has a CE course on AACD's Virtual Campus. To view, go to [AACD.com/virtualcampus](http://AACD.com/virtualcampus)

**Introduction**

Preparing anterior teeth for esthetic restorations can be a daunting task for any clinician. In order for the dental laboratory technician to create an ideal restoration, the dentist must be able to prepare and contour a tooth to ensure adequate reduction has been allotted. The use of preparation guides can increase the efficiency and efficacy of the preparation appointment by ensuring the process is predictable and accurate. This article provides a detailed description of how to fabricate four different preparation guides for an anterior esthetic case (**Fig 1**) as well as how to transfer the guides into the mouth to visualize how much reduction is needed for the final restorative material.



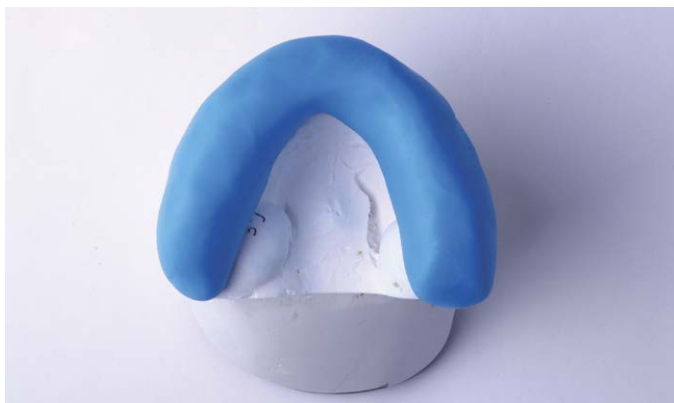**Figure 1:** The four preparation guides discussed in this article.



**Figure 2:** Equal amounts of catalyst and base putty material.



**Figure 3:** Cylinder shape used for preparation guide.



**Figure 4:** Adaptation of the putty over the facial, occlusal, and lingual surfaces.

## Preparation Guide Fabrication Steps

### Step 1: Begin with the End in Mind

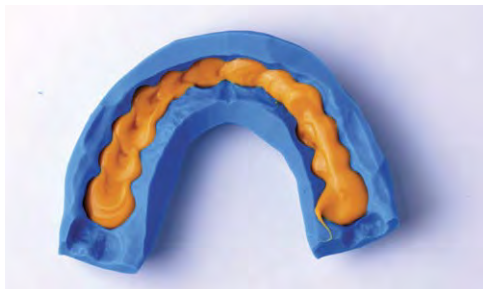
To achieve exceptional esthetic results, the dentist must begin with the end in mind. By beginning to visualize the end result during the treatment-planning phase, he or she can establish a diagnostic wax-up to act as a blueprint for the patient's functional esthetic matrix. These newly designed contours are based on the patient's esthetic and functional parameters.<sup>1</sup> Using preparation matrices created from the diagnostic wax-up enables the dentist to achieve better harmony and accuracy between the preparations and the definitive restorations by attempting to eliminate gross over- or under-reduction. Using preparation guides even allows him or her to visualize where no reduction is needed and where the use of no-preparation veneers could be a viable treatment option.<sup>2</sup>

### Step 2: Initial Depth-Cut Preparation Guide

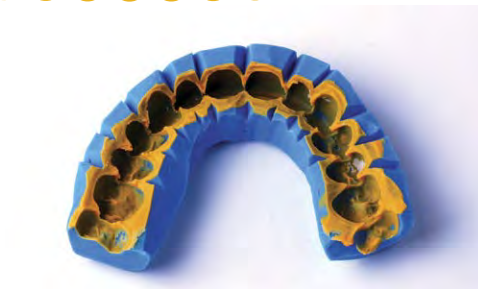The initial depth-cut guide serves two purposes: the first is to provide a bis-acryl transfer of the wax-up into the mouth for initial depth cuts to be made; the second is to shrink-wrap the provisional restorations onto the teeth once the preparations are complete. Starting with the diagnostic wax-up the lab has created, the guide is made from a firm catalyst/base putty and ultralight polyvinyl siloxane (PVS). Take equal amounts of the catalyst and base (Fig 2), knead them together to ensure a homogenous mix, roll the material into a cylinder (Fig 3), and press the cylinder down over the occlusal surfaces of the wax-up while also pressing the putty against the facial and lingual surfaces to ensure adequate adaptation (Fig 4). After the putty sets, remove it and reline the guide with an ultralight PVS wash (Fig 5), then readapt it to the wax-up to obtain an even higher level of detail. After the PVS is set, remove the guide and cut v-shaped notches in the embrasure areas to act as vents out of which excess bis-acryl material can flow (Fig 6). This guide will be loaded with bis-acryl temporary material and applied over the unprepared teeth at the start of the appointment.

The restorative material volume needed for veneer restorations can vary depending on preparation design, material, shade selection, strength considerations, and patient parafunctional habits. All of these factors must be considered prior to preparing the teeth in order to achieve a high success rate and avoid failures.<sup>3,4</sup> When practicing responsible esthetics, it is of the utmost importance to preserve as much enamel as possible when preparing anterior teeth. Ferrari and colleagues measured the average thickness of the facial enamel in different segments of the tooth and found that the enamel was only 0.3 to 0.5 mm thick in the gingival third, 0.6 to 1.0 mm in the middle third, and 1.0 to 2.1 mm in the incisal third.<sup>5</sup> Keeping the initial facial depth cut within 0.3 to 0.5 mm should help to limit most of the preparation to the enamel. Getting the lab involved early in the decision-making process can help to determine proper material selection and adequate reduction requirements while trying to remain as conservative as possible with the preparation.





**Figure 5:** Reline the putty guide with ultralight PVS wash material.



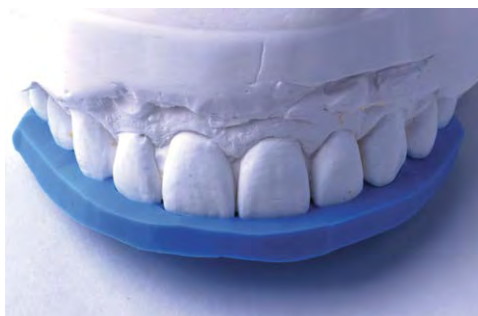**Figure 6:** V-shaped vent areas to allow release of excess bis-acryl.



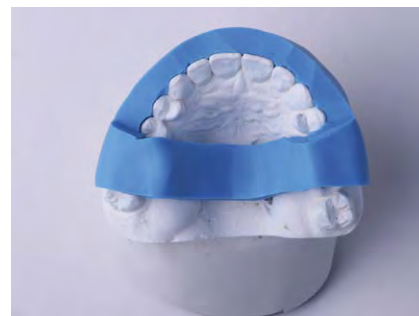**Figure 7:** Sphere shape for molding putty.



**Figure 8:** Adaptation of putty over incisal edges and palatal area.



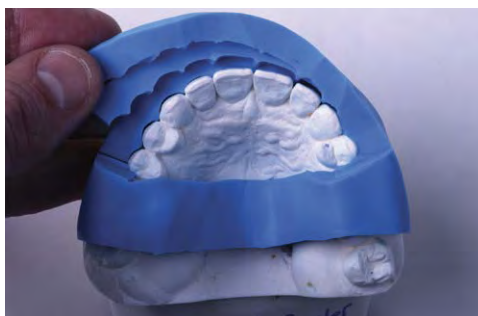**Figure 9:** Small amount of overlap of the newly proposed incisal edge.



**Figure 10:** Contiguous matrix resulting from adaptation for facial reduction guide.



**Figure 11:** Three horizontal slices and one vertical releasing incision on one side only.



**Figure 12:** Occlusal view of the guide while peeling back three different planes of facial reduction.

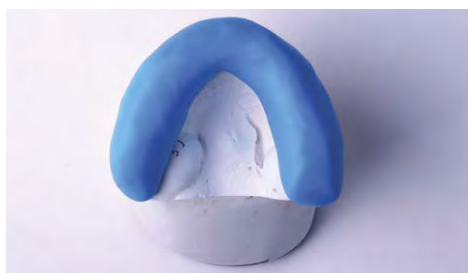### Step 3: Incisal Edge Preparation Guide

The second guide to be fabricated is the incisal edge matrix, which is created from putty as well. It is made by taking equal amounts of the catalyst and base putty, rolling them into a sphere (Fig 7), then adapting the material against the palate and molding it over the incisal edges of the wax-up (Figs 8 & 9). The palate and lingual surfaces of the teeth act as the rest seat for this particular guide, and it can be trimmed to remove any of the overlapped portion of the newly proposed incisal edge. This allows a better view when the guide is transferred to the mouth later in the procedure.

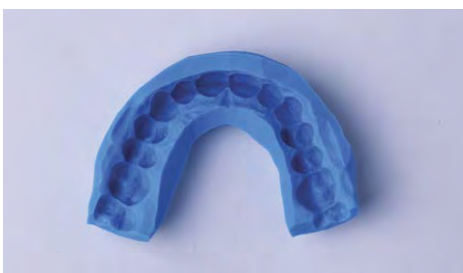For incisal edge reduction, Magne and Magne report the ideal thickness for developing incisal edge effects in porcelain to be 1.5 mm.<sup>6</sup> This will allow the ceramist to create a lifelike appearance, with translucency, lobular development, and color to reflect that of the natural dentition.<sup>7</sup>

### Step 4: Facial Preparation Guide

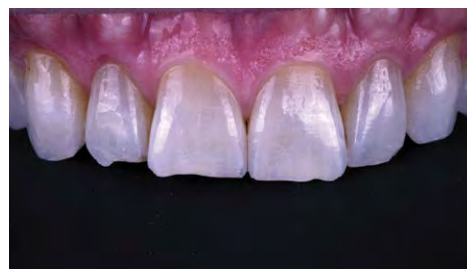In creating the three-plane facial reduction matrix, equal amounts of catalyst and base putty are mixed and rolled into a cylinder, then adapted over the facial surfaces of the wax-up. This is followed by crossing over the occlusal surfaces of the molars and connecting the ends of the cylinder on the palate, making it one contiguous matrix (Fig 10). The palate and the molars act as positive seats for the guide to rest. After the putty sets, the matrix is carefully sliced horizontally into the three facial planes, followed by one vertical releasing incision on one side only (Fig 11). This allows each section to be peeled back to check the preparation while the guide is placed in the mouth (Fig 12).



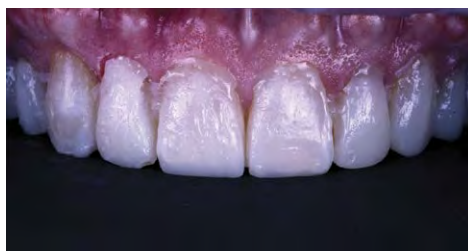**Figure 13:** Adaptation for facial and lingual reduction matrix.



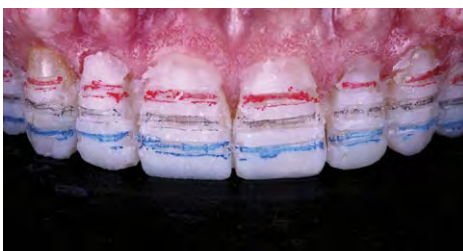**Figure 14:** Facial and lingual reduction guide without PVS relining material.



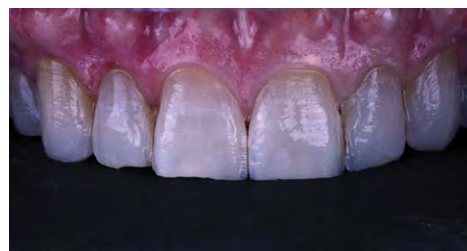**Figure 15:** Preoperative retracted view.



**Figure 16:** Bis-acryl transfer to unprepared teeth.



**Figure 17:** Depth cuts with graphite markings.



**Figure 18:** Initial preparation and removal of excess bis-acryl material.

## Step 5: Facial and Lingual/Occlusal Reduction Matrix and Making the Reductions

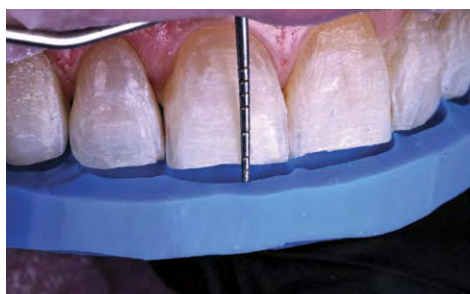The last matrix, the facial and lingual or occlusal reduction matrix, can be viewed as more of a vertical orientation compared with the previous matrices, which have been employed to visualize more mesiodistally or horizontally. This guide is particularly useful for checking the lingual clearance for full-coverage crowns; however, it also can be helpful in ensuring a distinct three-plane facial reduction. It is fabricated by mixing the catalyst and base putty and rolling them into a cylinder, then adapting it over the occlusal surfaces of the wax-up and ensuring intimate contact with the facial and lingual surfaces (Fig 13). This guide does not need to be relined with PVS (Fig 14).

Recommendations for occlusal clearance can vary greatly depending on the material selection, bonding/cementation protocols, and the manufacturer's guidelines. Pressed lithium disilicate restorations can range between 1.0 to 1.5 mm in material thickness on the occlusal or lingual, with a high rate of success for adhesively bonded restorations.<sup>8,9</sup> It is important to note that the clinician should understand and follow the manufacturer's guidelines for the strength tolerances of a particular material to ensure success.

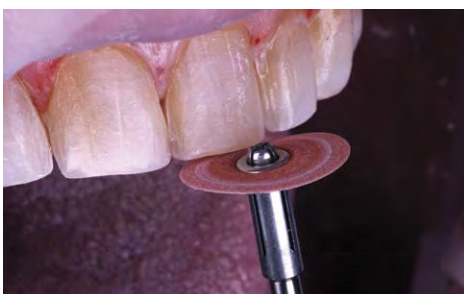## Step 6: Depth Cuts and Initial Preparation in the Mouth

Bis-acryl temporary material is placed in the depth-cutting guide, which is then placed over the unprepared teeth (Fig 15). After the material has had an initial set time of 1 minute 30 seconds, the excess material is removed from the vent areas while the material is still soft. Then delicately remove the guide, leaving the bis-acryl in place (Fig 16). At this time, the preparation procedure can begin, starting with the facial depth cuts (0.3 to 0.5 mm, depending on the previously determined parameters for the selected material). The goal for the facial preparation is a three-plane reduction in the gingival, middle, and incisal thirds. After the depth cuts are established, a graphite pencil can be used to demarcate the depth grooves (Fig 17). Once preparation has commenced, it can be difficult to decipher the depth groove that was initially established, so the graphite serves as a visual representation as to when the proper depth has been achieved. After completing the facial preparation of the bis-acryl, a 1.5-mm incisal depth cut can be made and prepared.

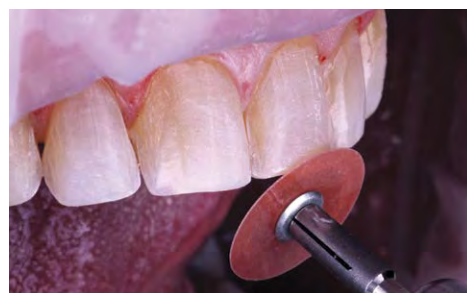After these very conservative initial preparations into the enamel, there may be areas of bis-acryl remaining on the teeth (Fig 18). This can be removed, as it is considered to be extra space that will be composed of porcelain later in the definitive restorations.



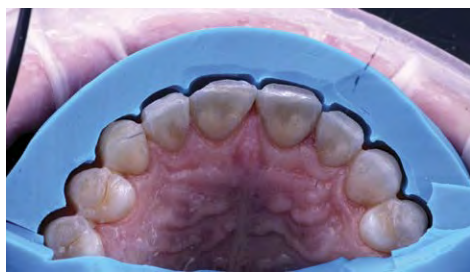**Figure 19:** Incisal edge reduction guide check using a periodontal probe.



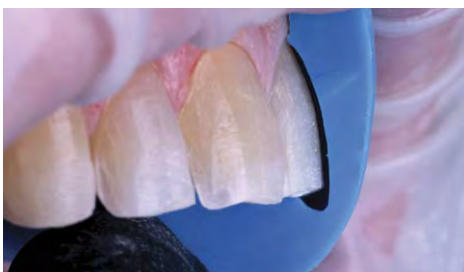**Figure 20:** Smoothing of the incisal edges to remove any irregularities.



**Figure 21:** Beveling of the labioincisal third to ensure adequate room for incisal edge effects in the definitive restorations.



**Figure 22:** Facial reduction guide displaying appropriate reduction in the embrasure areas.



**Figure 23:** Facial and lingual reduction check to show smooth convex preparation with uniform reduction.

### Step 7: Double-Check the Incisal Reduction

After the initial depth cuts and preparation, the other guides serve as a double-check for the preparations. By placing the incisal guide in the mouth and using a periodontal probe, it is easy to verify that 1.5 mm of space has been established (Fig 19). If there are any areas that are less than 1.5 mm, the guide is removed and the teeth are prepared to the appropriate amount. Then, use a disc (e.g., Sof-Lex, 3M; St. Paul, MN) to ensure the labioincisal third is smooth and does not have any sharp edges (Fig 20). When talking with ceramists, this is one of the most commonly under-reduced areas of a preparation (Fig 21).<sup>10</sup> If this area is under-reduced, the lab has two options: compromise the restoration's esthetics by not building in the incisal edge effects, or build the incisal edge effects, pushing the incisal edge more facially. The first option could hinder the restoration's natural esthetic appeal, while the second option could pose a problem for esthetics, phonetics, and the lip closure path.

### Step 8: Double-Check the Facial Reductions

Place the facial reduction guide into the mouth, resting it on the palate and the molars, and use an occlusal mirror to check the preparations, all the while keeping in mind the three planes of facial reduction. Touch up any under-reduced areas, then reevaluate. Pay close attention to achieving equal reduc-

tion across the tooth mesiodistally and into the proximal embrasure areas. Figure 22 shows that #6 facial is under-reduced and will require further preparation, whereas #8 distofacial is actually over-reduced and no more preparation is needed. Adequate reduction in the embrasure areas is necessary to provide the lab enough room to roll the porcelain into the interproximal area, giving an individualized appearance to the teeth. If there is inadequate reduction, the ceramist could end up making the teeth look wider than intended because he or she does not have the appropriate space to bend the porcelain past the line angles and into the interproximal area.<sup>11</sup> The facial/lingual reduction matrix can be used here as well to ensure a smooth convex preparation with proper reduction (Fig 23).

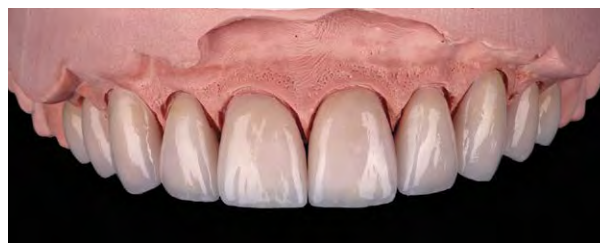### Step 9: Create the Provisional Restorations

After the tooth preparations are complete and the appropriate records have been taken for the lab, it is time to provisionalize the teeth using a shrink-wrapped provisional technique. Start by spot-etching the teeth, then apply a small amount of 2% chlorhexidine disinfectant (e.g., Consepsis, Ultradent Products; South Jordan, UT), followed by applying a bonding adhesive only to the spot-etched area. Light-cure, then load the bis-acryl temporary material into the original depth-cut guide and place over the now prepared teeth. Remove the excess material after 1 minute 30 seconds but leave the guide in place for an additional 3 minutes 30 seconds, allowing for a total cure

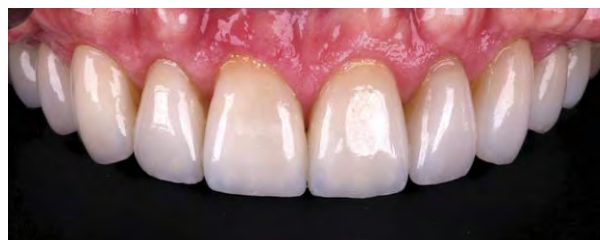



**Figure 24:** The approved provisional restorations.



**Figure 25:** The definitive lithium disilicate veneers.



**Figure 26:** Retracted postoperative view.

time of 5 minutes. The provisional restorations can then be trimmed, contoured, and polished, followed by the addition of a surface glaze for enhanced esthetics (Fig 24).

## Step 10: Fabricate the Definitive Restorations

Once the provisional restorations have been tested and approved by the patient for esthetics, phonetics, and function, they in turn become the blueprint for the definitive restorations.<sup>12</sup> The lab technician can cross-mount the facebow-approved provisionals and the master die model to begin to envision the space that has been provided. He or she will then create a putty matrix of the provisionals and apply that to the master die model. This serves as a three-dimensional representation of the space allowed for preparation in relation to the approved provisionals.<sup>13</sup> Any restoration that is fabricated beyond the putty matrix will not be representative of the contours that have been developed in the mouth, so it is of utmost importance to work with a ceramist who is capable of replicating and designing definitive restorations within the matrix (Fig 25). By providing optimal reduction through an outcome-driven preparation design and partnering with a lab that understands the process of working within the functional esthetic matrix, the definitive restorations simply will be a duplicate of the provisional restorations (Fig 26).

## Summary

A preparation guide is a visualization tool for dentists preparing anterior teeth for esthetic restorations. The process of designing a preparation based on the proposed end result can alleviate stress by allowing the dentist to ensure adequate re-

duction is provided to avoid issues during the laboratory fabrication of definitive restorations. It also increases efficiency by offering the dentist a predictable system that ultimately can streamline the preparation appointment.

## Acknowledgment

*The author thanks Shoji Suruga, CDT, AACD (Bay View Dental Laboratory; Chesapeake, VA) for the beautifully crafted porcelain veneers shown in this article.*

## References

1. Cranham J, Finlay S. Timeless principles in esthetic dentistry. *J Cosmetic Dent.* 2012;28(3):60-8.
2. LeSage B, Wells D. Myths versus realities: veneers and prep-less veneers. *J Cosmetic Dent.* 2011; 27(2):66-76.
3. Gurel G, Morimoto S, Calamita MA, Coachman C, Sesma N. Clinical performance of porcelain laminate veneers: outcomes of the aesthetic pre-evaluative temporary (APT) technique. *Int J Periodontics Restorative Dent.* 2012;32(6):624-35.
4. Farias-Neto A, de Medeiros FCD, Vilanova L, Simonetti Chaves M, Freire Batista de Araujo JJ. Tooth preparation for ceramic veneers: when less is more. *Int J Esthet Dent.* 2019;14(2):156-64.
5. Ferrari M, Patroni S, Ballers P. Measurement of enamel thickness in relation to reduction for etched laminate veneers. *Int J Periodontics Restorative Dent.* 1992;12(5):407-13.

6. Magne P, Magne M. Use of additive waxup and direct intraoral mock-up for enamel preservation with porcelain laminate veneers. *Eur J Esthet Dent.* 2006;1(1):10-9.
7. Santos A, Villarroel M, Villarroel A, Portales D. Different materials for different situations: ceramic solutions for specific restorative indications. *J Cosmetic Dent.* 2016;31(4):70-80.
8. Fabbri G, Zarone F, Dellificorelli G, Cannistraro G, De Lorenzi M, Mosca A, Sorrentino R. Clinical evaluation of 860 anterior and posterior lithium disilicate restorations: retrospective study with a mean follow-up of 3 years and a maximum observational period of 6 years. *Int J Periodontics Restorative Dent.* 2014;34(2):165-77.
9. Cortellini D, Canale A. Bonding lithium disilicate ceramic to feather-edge tooth preparations: a minimally invasive treatment concept. *J Adhesive Dent.* 2012;14(1):7-10.
10. Hess LA. Management of the incisal edge: the key to functional and esthetic success in anterior restorations. *Inside Dent.* 2013;9(10):56-64.
11. Olitsky J. Seven worst violations of smile design: achieve better esthetics by understanding common mistakes. *Inside Dent.* 2015;11(9):60-8.
12. Sesemann M. Diagnostic full-coverage provisionals for accurately communicating esthetic and functional. *Funct Esthet Restorative Dent.* 2008;2(2):8-14.
13. Dawson P. Anterior guidance and its relationship to smile design. In: *Functional occlusion: from TMJ to smile design.* St. Louis: Mosby; 2007. p. 159-75. **JCD**

“The use of preparation guides can increase the efficiency and efficacy of the preparation appointment by ensuring the process is predictable and accurate.”



Dr. Sisler maintains a private practice in Shippensburg, Pennsylvania; and is an associate faculty member of the Dawson Academy.

Disclosure: The author did not report any disclosures.

